

International Association of Dental Traumatology Guidelines for the Management of Traumatic Dental Injuries: 3. Injuries in the Primary Dentition

Endorsed by the American Academy
of Pediatric Dentistry



How to Cite: Day PF, Flores MT, O'Connell AC, et al. International Association of Dental Traumatology guidelines for the management of traumatic dental injuries: 3. Injuries in the primary dentition. *Dent Traumatol* 2020;36(4):343-359. <https://doi.org/10.1111/edt.12576>.

2020

Authors

Peter F. Day¹ • Marie Therese Flores² • Anne C. O'Connell³ • Paul V. Abbott⁴ • Georgios Tsilingaridis^{5,6} • Ashraf F. Fouad⁷ • Nestor Cohenca⁸ • Eva Lauridsen⁹ • Cecilia Bourguignon¹⁰ • Lamar Hicks¹¹ • Jens Ove Andreasen¹² • Zafer C. Cehreli¹³ • Stephen Harlamb¹⁴ • Bill Kahler¹⁵ • Adeleke Oginni¹⁶ • Marc Semper¹⁷ • Liran Levin¹⁸

Abstract

Traumatic injuries to the primary dentition present special problems that often require far different management when compared to that used for the permanent dentition. The International Association of Dental Traumatology (IADT) has developed these Guidelines as a consensus statement after a comprehensive review of the dental literature and working group discussions. Experienced researchers and clinicians from various specialties and the general dentistry community were included in the working group. In cases where the published data did not appear conclusive, recommendations were based on the consensus opinions or majority decisions of the working group. They were then reviewed and approved by the members of the IADT Board of Directors. The primary goal of these Guidelines is to provide clinicians with an approach for the immediate or urgent care of primary teeth injuries based on the best evidence provided by the literature and expert opinions. The IADT cannot, and does not, guarantee favorable outcomes from strict adherence to the Guidelines; however, the IADT believes their application can maximize the probability of favorable outcomes. (*Dental Traumatology* 2020;36(4):343-359; doi: 10.1111/edt.12576) Received May 19, 2020 | Accepted May 19 2020.

KEYWORDS: AVULSION, LUXATION, PREVENTION, TOOTH FRACTURE, TRAUMA

¹School of Dentistry, University of Leeds and Community Dental Service Bradford District Care NHS Trust, Leeds, UK. ²Department of Pediatric Dentistry, Faculty of Dentistry, Universidad de Valparaíso, Valparaíso, Chile. ³Paediatric Dentistry, Dublin Dental University Hospital, Trinity College Dublin, The University of Dublin, Dublin, Ireland. ⁴UWA Dental School, University of Western Australia, Nedlands, WA, Australia. ⁵Division of Orthodontics and Pediatric Dentistry, Department of Dental Medicine, Karolinska Institutet, Huddinge, Sweden. ⁶Center for Pediatric Oral Health Research, Stockholm, Sweden. ⁷Adams School of Dentistry, University of North Carolina, Chapel Hill, NC, USA. ⁸Department of Pediatric Dentistry, University of Washington and Seattle Children's Hospital, Seattle, WA, USA. ⁹Resource Center for Rare Oral Diseases, Copenhagen University Hospital, Copenhagen, Denmark. ¹⁰Specialist Private Practice, Paris, France. ¹¹Division of Endodontics, University of Maryland School of Dentistry, UMB, Baltimore, MD, USA. ¹²Department of Oral and Maxillofacial Surgery, Resource Centre for Rare Oral Diseases, University Hospital in Copenhagen (Rigshospitalet), Copenhagen, Denmark. ¹³Department of Pediatric Dentistry, Faculty of Dentistry, Hacettepe University, Ankara, Turkey. ¹⁴Faculty of Medicine and Health, The University of Sydney, Sydney, NSW, Australia. ¹⁵School of Dentistry, The University of Queensland, St Lucia, Qld, Australia. ¹⁶Faculty of Dentistry, College of Health Sciences, Obafemi Awolowo University, Ile-Ife, Nigeria. ¹⁷Specialist Private Practice, Bremen, Germany. ¹⁸Faculty of Medicine and Dentistry, University of Alberta, Edmonton, AB, Canada.

Correspondence: Liran Levin, Chair of the IADT Guidelines Committee, Faculty of Medicine & Dentistry, University of Alberta, 5-468 Edmonton Clinic Health Academy, 11405-87 Avenue NW, 5th Floor, Edmonton, AB T6G 1C9, Canada.
Email: liran@ualberta.ca

1 | INTRODUCTION

Injuries to children are a major threat to their health, and they are generally a neglected public health problem.¹ For children, aged 0-6 years, oral injuries account for 18% of all physical injuries and the mouth is the second most common area of the body to be injured.² A recent meta-analysis on traumatic dental injuries (TDIs) reveals a world prevalence of 22.7% affecting the primary teeth.³ Repeated TDIs are also frequently seen in children.⁴

Unintentional falls, collisions, and leisure activities are the most common reasons for TDIs, especially as children learn to crawl, walk, run, and embrace their physical environment.⁵ They most commonly occur between 2 and 6 years of age⁴⁻⁷ with injuries to periodontal tissues occurring most frequently.^{6,8} Children with these injuries present to many healthcare settings, including general dental practitioners, emergency medical services, pharmacists, community dental clinics, and specialist dental services. Consequently, each service provider needs to have the appropriate knowledge, skills, and training in how to care for children with TDIs to their primary dentition.

The primary teeth Guidelines contain recommendations for the diagnosis and management of traumatic injuries to the primary dentition, assuming the child is medically healthy with a sound and caries-free primary dentition. Management strategies may change where multiple teeth are injured. Many articles have contributed to the content of these Guidelines and the treatment tables (1-12) and these articles are not mentioned elsewhere in this introductory text.⁹⁻¹⁵

Reprinted with permission of John Wiley and Sons.

© 2020 The Authors. *Dental Traumatology* 2020;36(4):343-359. Available at: "<https://onlinelibrary.wiley.com/doi/abs/10.1111/edt.12576>".
Dental Traumatology is published for the International Association of Dental Traumatology (IADT) by John Wiley and Sons Ltd.

1.1 | Initial presentation and minimizing anxiety to the child and parent

Management of TDIs in children is distressing for both the child and the parents. It can also be challenging for the dental team. A TDI in the primary dentition often may be the reason for the child's first visit to the dentist. Minimizing anxiety for the child and parents, or other caregivers, during the initial visit is essential. At this young age, the child may resist co-operating for an extensive examination, radiographs, and treatment. Knee-to-knee examination can be helpful in examining a young child. Information about how to undertake an examination of a child with a TDI involving their primary dentition can be found in current textbooks^{16–18} or can be viewed in the following video (<https://tinyurl.com/kneetokneeexamination>). Wherever possible, the acute and follow-up dental care should be provided by a child-oriented team that has experience and expertise in the management of pediatric oral injuries. These teams are best placed to access specialist diagnostic and treatment services, including sedation and general anesthesia, and pain management for the prevention or minimization of suffering.¹⁹

1.2 | A structured approach

It is essential that clinicians adopt a structured approach to managing traumatic dental injuries. This includes history taking, undertaking the clinical examination, collecting test results, and how this information is recorded. The literature shows that the use of a structured history at the initial consultation leads to a significant improvement in the quality of the trauma records involving the permanent dentition^{5,20}. There are a variety of structured histories available in current textbooks^{16–18} or used at different specialist centers.^{21,22} Extra-oral and intra-oral photographs act as a permanent record of the injuries sustained and are strongly recommended.

1.3 | Initial assessment

Elicit a careful medical, social (including those who attend with the child), dental, and accident history. Thoroughly examine the head and neck and intra-orally for both bony and soft tissue injuries.^{17,18} Be alert to concomitant injuries including head injury, facial fractures, missing tooth fragments, or lacerations. Seek a medical examination if necessary.

1.4 | Soft tissue injuries

It is essential to identify, record, and diagnose extra-oral and intraoral soft tissue injuries.^{18,23} The lips, oral mucosa, attached and free gingivae, and the frenula should be checked for lacerations and hematomas. The lips should be examined for possible embedded tooth fragments. The presence of a soft tissue injury is strongly associated with the pursuit of immediate care. Such injuries are most commonly found in the 0- to 3-year age group.²⁴ Management of soft tissues, beyond just first aid, should be provided by a child-oriented team with experience in pediatric oral injuries. Parental engagement with the homecare for soft tissue injuries to the gingivae is critical and will influence the outcomes for healing of the teeth and soft tissues. Parental homecare instructions for intra-oral soft tissue injuries are described later in these Guidelines.

1.5 | Tests, crown discoloration, and radiographs

Extra-oral and intra-oral photographs are strongly recommended.

Pulp sensibility tests are unreliable in primary teeth and are therefore not recommended.

Tooth mobility, color, tenderness to manual pressure, and the position or displacement should be recorded.

The color of injured and uninjured teeth should be recorded at each clinic visit. Discoloration is a common complication following luxation injuries.^{8,25–27} This discoloration may fade, and the tooth may regain its original shade over a period of weeks or months.^{8,28–30} Teeth with persistent dark discoloration may remain asymptomatic clinically and radiographically normal, or they may develop apical periodontitis (with or without symptoms).^{31,32} Root canal

treatment is not indicated for discolored teeth unless there are clinical or radiographic signs of infection of the root canal system.^{18,33}

Every effort has been made in these Guidelines to reduce the number of radiographs needed for accurate diagnosis, thus minimizing a child's exposure to radiation. For essential radiographs, radiation protection includes the use of a thyroid collar where the thyroid is in the path of the primary X-ray beam and a lead apron for when parents are holding the child. Radiation-associated risks for children are a concern as they are substantially more susceptible to the effects of radiation exposure for the development of most cancers than adults. This is due to their longer life expectancy and the acute radiosensitivity of some developing organs and tissues.^{34,35} Therefore, clinicians should question each radiograph they take and cognitively ask whether additional radiographs will positively affect the diagnosis or treatment provided for the child. Clinicians must work within the ALARA (As Low As Reasonably Achievable) principles to minimize the radiation dose. The use of CBCT following TDI in young children is rarely indicated.³⁶

1.6 | Diagnosis

A careful and systematic approach to diagnosis is essential. Clinicians should identify all injuries to each tooth including both hard tissues injuries (eg, fractures) and periodontal injuries (eg, luxations). When concomitant injuries occur in the primary dentition following extrusion and lateral luxation injuries, they have a detrimental impact on pulp survival.²⁷ The accompanying tables (1–12) and the trauma pathfinder diagram (www.dentaltraumaguide.org) help clinicians identify all possible injuries for each injured tooth.

1.7 | Intentional (non-accidental) injuries

Dental and facial trauma can occur in cases of intentional injuries. Clinicians should check whether the history of the accident and the injuries sustained are consistent or match. In situations where there is suspicion of abuse, prompt referral for a full physical examination and investigation of the incident should be arranged. Referral should follow local protocols, which is beyond the scope of these Guidelines.

1.8 | Impact of orofacial and primary tooth trauma on the permanent dentition

There is a close spatial relationship between the apex of the primary tooth root and the underlying permanent tooth germ. Tooth malformation, impacted teeth, and eruption disturbances in the developing permanent dentition are some of the consequences that can occur following injuries to primary teeth and the alveolar bone.^{37–43} Intrusion and avulsion injuries are most commonly associated with the development of anomalies in the permanent dentition.^{37–42}

For intrusive and lateral luxation injuries, previous Guidelines have recommended the immediate extraction of the traumatized primary tooth if the direction of displacement of the root is toward the permanent tooth germ. This action is no longer advised due to (a) evidence of spontaneous re-eruption for intruded primary teeth,^{8,10,26,43–45} (b) the concern that further damage may be inflicted on the tooth germ during extraction, and (c) the lack of evidence that immediate extraction will minimize further damage to the permanent tooth germ.

It is very important to document that parents have been informed about possible complications to the development of the permanent teeth, especially following intrusion, avulsion, and alveolar fractures.

1.9 | Management strategy for injuries to the primary dentition

In general, there is limited evidence to support many of the treatment options in the primary dentition. Observation is often the most appropriate option in the emergency situation unless there is risk of aspiration, ingestion, or interference with the occlusion. This conservative approach may reduce additional suffering for the child¹⁸ and the risk of further damage to the permanent dentition.^{18,46,47}

Reprinted with permission of John Wiley and Sons.

© 2020 The Authors. *Dental Traumatology* 2020;36(4):343–359. Available at: "<https://onlinelibrary.wiley.com/doi/abs/10.1111/edt.12576>".
Dental Traumatology is published for the International Association of Dental Traumatology (IADT) by John Wiley and Sons Ltd.

TABLE 1 Treatment guidelines for primary teeth: Enamel fractures

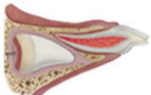
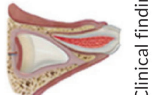
| Enamel fracture | Radiographic recommendations | Treatment | Follow up | Favorable outcomes | Unfavorable outcomes |
|---|--|--|---|--|---|
|  <p>Clinical findings: Fracture involves enamel only</p> | <ul style="list-style-type: none"> No radiographs recommended | <ul style="list-style-type: none"> Smooth any sharp edges. Parent/patient education: <ul style="list-style-type: none"> Exercise care when eating not to further traumatize the injured tooth while encouraging a return to normal function as soon as possible. Encourage gingival healing and prevent plaque accumulation by parents cleaning the affected area with a soft brush or cotton swab combined with an alcohol-free 0.1 to 0.2% chlorhexidine gluconate mouth rinse applied topically twice a day for 1 wk | <ul style="list-style-type: none"> No clinical or radiographic follow up recommended | <ul style="list-style-type: none"> Asymptomatic Pulp healing with: <ul style="list-style-type: none"> Normal color of the remaining crown No signs of pulp necrosis and infection Continued root development in immature teeth | <ul style="list-style-type: none"> Symptomatic Crown discoloration Signs of pulp necrosis and infection—such as: <ul style="list-style-type: none"> Sinus tract, gingival swelling, abscess, or increased mobility Persistent dark gray discoloration with one or more other signs of infection Radiographic signs of pulp necrosis and infection No further root development of immature teeth |

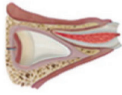
TABLE 2 Treatment guidelines for primary teeth: Enamel-dentin fractures (with no pulp exposure)

| Enamel-dentin fracture (with no pulp exposure) | Radiographic recommendations | Treatment | Follow up | Favorable outcome | Unfavorable outcome |
|---|--|--|--|--|--|
|  <p>Clinical findings: Fracture involves enamel and dentin. The pulp is not exposed</p> <ul style="list-style-type: none"> The location of missing tooth fragments should be explored during the trauma history and examination, especially when the accident was not witnessed by an adult or there was a loss of consciousness Note: While fragments are most often lost out of the mouth, there is a risk that they can be embedded in the soft tissues, ingested, or aspirated | <ul style="list-style-type: none"> Baseline radiograph optional Take a radiograph of the soft tissues if the fractured fragment is suspected to be embedded in the lips, cheeks, or tongue | <ul style="list-style-type: none"> Cover all exposed dentin with glass ionomer or composite Lost tooth structure can be restored using composite immediately or at a later appointment Parent/patient education: <ul style="list-style-type: none"> Exercise care when eating not to further traumatize the injured tooth while encouraging a return to normal function as soon as possible Encourage gingival healing and prevent plaque accumulation by parents cleaning the affected area with a soft brush or cotton swab combined with an alcohol-free 0.1 to 0.2% chlorhexidine gluconate mouth rinse applied topically twice a day for 1 wk | <ul style="list-style-type: none"> Clinical examination after 6-8 wk Radiographic follow up indicated only when clinical findings are suggestive of pathosis (eg, signs of pulp necrosis and infection) Parents should watch for any unfavorable outcomes. If seen, the child needs to return to the clinic as soon as possible. When unfavorable outcomes are identified, treatment is often required The follow-up treatment, which frequently requires the expertise of a child-oriented team, is outside the scope of these guidelines | <ul style="list-style-type: none"> Asymptomatic Pulp healing with: <ul style="list-style-type: none"> Normal color of the remaining crown No signs of pulp necrosis and infection Continued root development in immature teeth | <ul style="list-style-type: none"> Symptomatic Crown discoloration Signs of pulp necrosis and infection—such as: <ul style="list-style-type: none"> Sinus tract, gingival swelling, abscess, or increased mobility Persistent dark gray discoloration with one or more other signs of discoloration with one or more other signs of root canal infection Radiographic signs of pulp necrosis and infection No further root development of immature teeth |

Reprinted with permission of John Wiley and Sons.

© 2020 The Authors. *Dental Traumatology* 2020;36(4):343-359. Available at: <https://onlinelibrary.wiley.com/doi/abs/10.1111/edt.12576>.
Dental Traumatology is published for the International Association of Dental Traumatology (IADT) by John Wiley and Sons Ltd.

TABLE 3 Treatment guidelines for primary teeth: Complicated crown fractures (with pulp exposure)

| Complicated crown fracture (ie, with exposed pulp) | | Radiographic recommendations | Treatment | Follow up | Favorable outcome | Unfavorable outcome |
|---|--|--|--|--|--|---------------------|
| <p></p> <p>Clinical findings: Fracture involves enamel and dentin plus the pulp is exposed.</p> <ul style="list-style-type: none"> The location of missing tooth fragments should be explored during the trauma history and examination, especially when the accident was not witnessed by an adult or there was a loss of consciousness Note: While fragments are most often lost out of the mouth, there is a risk that they can be embedded in the soft tissues, ingested, or aspirated | <ul style="list-style-type: none"> A periapical radiograph (using a size 0 sensor/film and the paralleling technique) or an occlusal radiograph (with a size 2 sensor/film) should be taken at the time of initial presentation for diagnostic purposes and to establish a baseline Take a radiograph of the soft tissues if the fractured fragment is suspected to be embedded in the lips, cheeks, or tongue | <ul style="list-style-type: none"> Preserve the pulp by partial pulpotomy. Local anesthesia will be required. A non-setting calcium hydroxide paste should be applied over the pulp and cover this with a glass ionomer cement and then a composite resin. Cervical pulpotomy is indicated for teeth with large pulp exposures. The evidence for using other biomaterials such as non-staining calcium silicate-based cements is emerging. Clinicians should focus on appropriate case selection rather than the material used Treatment depends on the child's maturity and ability to tolerate procedures. Therefore, discuss different treatment options (including pulpotomy) with the parents. Each option is invasive and has the potential to cause long-term dental anxiety. Treatment is best performed by a child-oriented team with experience and expertise in the management of pediatric dental injuries. Often no treatment may be the most appropriate option in the emergency situation, but only when there is the potential for rapid referral (within several days) to the child-oriented team Parent/patient education: <ul style="list-style-type: none"> Exercise care when eating not to further traumatize the injured tooth while encouraging a return to normal function as soon as possible. To encourage gingival healing and prevent plaque accumulation, parents should clean the affected area with a soft brush or cotton swab combined with an alcohol-free 0.1 to 0.2% chlorhexidine gluconate mouth rinse applied topically twice a day for 1 wk | <ul style="list-style-type: none"> Clinical examination after: <ul style="list-style-type: none"> 1 wk 6-8 wk 1 y Radiographic follow up at 1 y following pulpotomy or root canal treatment. Other radiographs are only indicated where clinical findings are suggestive of pathosis (eg, an unfavorable outcome) Parents should watch for any unfavorable outcomes. If seen, the child needs to return to the clinic as soon as possible. Where unfavorable outcomes are identified, treatment is often required. The follow-up treatment, which frequently requires the expertise of a child-oriented team, is outside the scope of these guidelines | <ul style="list-style-type: none"> Asymptomatic Pulp healing with: <ul style="list-style-type: none"> Normal color of the remaining crown No signs of pulp necrosis and infection Continued root development in immature teeth | <ul style="list-style-type: none"> Symptomatic Crown discoloration Signs of pulp necrosis and infection—such as: <ul style="list-style-type: none"> Sinus tract, gingival swelling, abscess, or increased mobility Persistent dark gray discoloration with one or more signs of root canal infection Radiographic signs of pulp necrosis and infection No further root development of immature teeth | |

Reprinted with permission of John Wiley and Sons.

© 2020 The Authors. *Dental Traumatology* 2020;36(4):343-359. Available at: "https://onlinelibrary.wiley.com/doi/abs/10.1111/edt.12576". *Dental Traumatology* is published for the International Association of Dental Traumatology (IADT) by John Wiley and Sons Ltd.

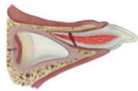
TABLE 4 Treatment guidelines for primary teeth: Crown-root fractures

| Crown-root fracture | | Radiographic recommendations | Treatment | Follow up | Favorable outcome | Unfavorable outcome |
|---|--|--|---|--|--|---------------------|
|  <p>Clinical findings: Fracture involves enamel, dentin, and root; the pulp may or may not be exposed (ie, complicated or uncomplicated)</p> <ul style="list-style-type: none"> Additional findings may include loose, but still attached, fragments of tooth | <ul style="list-style-type: none"> A periapical radiograph (using a size 0 sensor/film and the paralleling technique) or an occlusal radiograph (with a size 2 sensor/film) should be taken at the time of initial presentation for diagnostic purposes and to establish a baseline | <ul style="list-style-type: none"> Often no treatment may be the most appropriate option in the emergency situation, but only when there is the potential for rapid referral (within several days) to a child-oriented team If treatment is considered at the emergency appointment, local anesthesia will be required Remove the loose fragment and determine if the crown can be restored Option A: <ul style="list-style-type: none"> If restorable and no pulp exposed, cover the exposed dentine with glass ionomer If restorable and the pulp is exposed, perform a pulpotomy (see crown fracture with exposed pulp) or root canal treatment, depending on the stage of root development and the level of the fracture. Option B: <ul style="list-style-type: none"> If unrestorable, extract all loose fragments taking care not to damage the permanent successor tooth and leave any firm root fragment in situ, or extract the entire tooth Treatment depends on the child's maturity and ability to tolerate the procedure. Therefore, discuss treatment options (including extraction) with the parents. Each option is invasive and has the potential to cause long-term dental anxiety. Treatment is best performed by a child-oriented team with experience and expertise in the management of pediatric dental injuries Parent/patient education: <ul style="list-style-type: none"> Exercise care when eating not to further traumatize the injured tooth while encouraging a return to normal function as soon as possible To encourage gingival healing and prevent plaque accumulation, parents should clean the affected area with a soft brush or cotton swab combined with an alcohol-free 0.1% to 0.2% chlorhexidine gluconate mouth rinse applied topically twice a day for 1 wk | <ul style="list-style-type: none"> Where tooth is retained, clinical examination after: <ul style="list-style-type: none"> 1 wk 6-8 wk 1 y Radiographic follow up after 1 y following pulpotomy or root canal treatment. Other radiographs only indicated where clinical findings are suggestive of pathosis (eg, an unfavorable outcome) Parents should watch for any unfavorable outcomes. If seen, the child needs to return to the clinic as soon as possible. Where unfavorable outcomes are identified, treatment is often required The follow-up treatment, which frequently requires the expertise of a child-oriented team, is outside the scope of these guidelines | <ul style="list-style-type: none"> Asymptomatic Pulp healing with: <ul style="list-style-type: none"> Normal color of the remaining crown No signs of pulp necrosis and infection Continued root development in immature teeth Radiographic signs of pulp necrosis and infection No further root development of immature teeth | <ul style="list-style-type: none"> Symptomatic Crown discoloration Signs of pulp necrosis and infection—such as: <ul style="list-style-type: none"> Sinus tract, gingival swelling, abscess, or increased mobility Persistent dark gray discoloration with one or more signs of root canal infection Radiographic signs of pulp necrosis and infection No further root development of immature teeth | |

Reprinted with permission of John Wiley and Sons.

© 2020 The Authors. *Dental Traumatology* 2020;36(4):343-359. Available at: <https://onlinelibrary.wiley.com/doi/abs/10.1111/edt.12576>.
Dental Traumatology is published for the International Association of Dental Traumatology (IADT) by John Wiley and Sons Ltd.


TABLE 5 Treatment guidelines for primary teeth: Root fractures

| Radiographic recommendations and findings | | Treatment | Follow up | Favorable outcome | Unfavorable outcome |
|---|--|--|---|---|--|
| Root fracture | <p></p> <ul style="list-style-type: none"> A periapical (size 0 sensor/film, paralleling technique) or occlusal radiograph (size 2 sensor/film) should be taken at the time of initial presentation for diagnostic purposes and to establish a baseline The fracture is usually located mid-root or in the apical third | <ul style="list-style-type: none"> If the coronal fragment is not displaced, no treatment is required If the coronal fragment is displaced and is not excessively mobile, leave the coronal fragment to spontaneously reposition even if there is some occlusal interference If the coronal fragment is displaced, excessively mobile and interfering with occlusion, two options are available, both of which require local anesthesia <ul style="list-style-type: none"> Option A: <ul style="list-style-type: none"> Extract only the loose coronal fragment. The apical fragment should be left in place to be resorbed Option B: <ul style="list-style-type: none"> Gently reposition the loose coronal fragment. If the fragment is unstable in its new position, stabilize the fragment with a flexible splint attached to the adjacent uninjured teeth. Leave the splint in place for 4 wk The treatment depends on the child's maturity and ability to tolerate the procedure. Therefore, discuss treatment options with the parents. Each option is invasive and has the potential to cause long-term dental anxiety. Treatment is best performed by a child-oriented team with experience and expertise in the management of pediatric dental injuries. Often no treatment may be the most appropriate option in the emergency scenario, but only when there is the potential for rapid referral (within several days) to the child-oriented team Parent/patient education: <ul style="list-style-type: none"> Exercise care when eating not to further traumatize the injured tooth while encouraging a return to normal function as soon as possible To encourage gingival healing and prevent plaque accumulation, parents should clean the affected area with a soft brush or cotton swab combined with an alcohol-free 0.1%-0.2% chlorhexidine gluconate mouth rinse applied topically twice a day for 1 wk | <ul style="list-style-type: none"> Where no displacement of coronal fragment, clinical examination after: <ul style="list-style-type: none"> 1 wk 6-8 wk 1 y and where there are clinical concerns that an unfavorable outcome is likely. Then continue clinical follow up each year until eruption of permanent teeth If coronal fragment has been repositioned and splinted, clinical examination after: <ul style="list-style-type: none"> 1 wk 4 wk for splint removal 8 wk 1 y If coronal fragment has been extracted, clinical examination after 1 y Where there are concerns that an unfavorable outcome is likely, then continue clinical follow up each year until eruption of permanent teeth Radiographic follow up only indicated where clinical findings are suggestive of pathosis (eg, an unfavorable outcome) Parents should be informed to watch for any unfavorable outcomes and the need to return to the clinic as soon as possible. Where unfavorable outcomes are identified, treatment is often required. The follow-up treatment, which frequently requires the expertise of a child-oriented team, is outside the scope of these guidelines | <ul style="list-style-type: none"> Asymptomatic Pulp healing with: <ul style="list-style-type: none"> Normal color of the crown or transient red/gray or yellow discoloration and pulp canal obliteration No signs of pulp necrosis and infection Continued root development in immature teeth Realignment of the root-fractured tooth No mobility Resorption of the apical fragment | <ul style="list-style-type: none"> Symptomatic Signs of pulp necrosis and infection—such as: <ul style="list-style-type: none"> Sinus tract, gingival swelling, abscess, or increased mobility Persistent dark gray discoloration with one or more signs of root canal infection Radiographic signs of pulp necrosis and infection Radiographic signs of infection-related (inflammatory) resorption No further root development of immature teeth No improvement in the position of the root-fractured tooth |

Reprinted with permission of John Wiley and Sons.

© 2020 The Authors. *Dental Traumatology* 2020;36(4):343-359. Available at: "https://onlinelibrary.wiley.com/doi/abs/10.1111/edt.12576". *Dental Traumatology* is published for the International Association of Dental Traumatology (IADT) by John Wiley and Sons Ltd.

TABLE 6 Treatment guidelines for primary teeth: Alveolar fractures

| Alveolar fracture | | Radiographic recommendations and findings | | Treatment | | Follow up | | Favorable and unfavorable outcomes include some, but not necessarily all, of the following | |
|---|---|---|--|--|---|-------------------|---------------------|--|---------------------|
| Alveolar fracture | | Radiographic recommendations and findings | Treatment | Treatment | Follow up | Favorable outcome | Unfavorable outcome | Favorable outcome | Unfavorable outcome |
|  <p>Clinical findings: The fracture involves the alveolar bone (labial and palatal/lingual) and may extend to the adjacent bone</p> <ul style="list-style-type: none"> • Mobility and dislocation of the segment with several teeth moving together are common findings • Occlusal interference is usually present | <ul style="list-style-type: none"> • A periapical (size 0 sensor/film, paralleling technique) or occlusal radiograph (size 2 sensor/film) should be taken at the time of initial presentation for diagnostic purposes and to establish a baseline • A lateral radiograph may give information about the relationship between the maxillary and mandibular dentitions and if the segment is displaced in a labial direction • Fracture lines may be located at any level, from the marginal bone to the root apex or beyond, and they may involve the primary teeth and/or their permanent successors • Further imaging may be needed to visualize the extent of the fracture(s) but only where it is likely to change the treatment provided. | <ul style="list-style-type: none"> • Reposition (under local anesthesia) any displaced segment which is mobile and/or causing occlusal interference • Stabilize with a flexible splint to the adjacent uninjured teeth for 4 wk • Treatment should be performed by a child-oriented team with experience and expertise in the management of pediatric dental injuries • Parent/patient education: <ul style="list-style-type: none"> - Exercise care when eating not to further traumatize the injured teeth while encouraging a return to normal function as soon as possible - To encourage gingival healing and prevent plaque accumulation, parents should clean the affected area with a soft brush or cotton swab combined with an alcohol-free 0.1%-0.2% chlorhexidine gluconate mouth rinse applied topically twice a day for 1 wk | <ul style="list-style-type: none"> • Clinical examination after: <ul style="list-style-type: none"> - 1 wk - 4 wk for splint removal - 8 wk - 1 Y - Further follow up at 6 y of age is indicated to monitor eruption of the permanent teeth • Radiographic follow up at 4 w and 1 y to assess impact on the primary tooth and the permanent tooth germs in the line of the alveolar fracture. This radiograph may indicate a more frequent follow-up regimen is needed. Other radiographs are indicated only where clinical findings are suggestive of pathosis (eg, an unfavorable outcome) • If the fracture line is located at the level of the primary root apex, an abscess can develop. A periapical radiolucency can be seen on the radiograph • Parents should be informed to watch for any unfavorable outcomes and the need to return to the clinic as soon as possible. Where unfavorable outcomes are identified, treatment is often required • The follow-up treatment, which frequently requires the expertise of a child-oriented team, is outside the scope of these guidelines | <ul style="list-style-type: none"> • Asymptomatic • Pulp healing with: <ul style="list-style-type: none"> - Normal crown color or transient red/gray or yellow discoloration and pulp canal obliteration - No signs of pulp necrosis and infection - Continued root development in immature teeth • Periodontal healing • Realignment of the alveolar segment with the original occlusion restored • No disturbance to the development and/or eruption of the permanent successor | <ul style="list-style-type: none"> • Symptomatic • Signs of pulp necrosis and infection—such as: <ul style="list-style-type: none"> - Sinus tract, gingival swelling, abscess, or increased mobility - Persistent dark gray discoloration plus one or more signs of root canal infection - Radiographic signs of pulp necrosis and infection including infection-related (inflammatory) resorption • No further root development in immature teeth • Limited or no improvement in the position of the displaced segment and the original occlusion is not re-established • Negative impact on the development and/or eruption of the permanent successor | | | | |

Reprinted with permission of John Wiley and Sons.

© 2020 The Authors. *Dental Traumatology* 2020;36(4):343-359. Available at: "<https://onlinelibrary.wiley.com/doi/abs/10.1111/edt.12576>". *Dental Traumatology* is published for the International Association of Dental Traumatology (IADT) by John Wiley and Sons Ltd.

TABLE 7 Treatment guidelines for primary teeth: Concussion

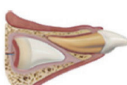

| Favorable and unfavorable outcomes include some, but not necessarily all, of the following | |
|---|---|
| Favorable outcome | Unfavorable outcome |
| <p>Concussion</p>  <p>Clinical findings: The tooth is tender to touch but it has not been displaced</p> <ul style="list-style-type: none"> It has normal mobility and no sulcular bleeding <p>Radiographic recommendations</p> <ul style="list-style-type: none"> No baseline radiograph recommended Parent/patient education: <ul style="list-style-type: none"> Exercise care when eating injured tooth while encouraging a return to normal function as soon as possible To encourage gingival healing and prevent plaque accumulation, parents should clean the affected area with a soft brush or cotton swab combined with an alcohol-free 0.1%–0.2% mouth rinse chlorhexidine gluconate applied topically twice a day for 1 wk <p>Treatment</p> <ul style="list-style-type: none"> No treatment is needed. Observation Parent/patient education: <ul style="list-style-type: none"> Exercise care when eating not to further traumatize the injured teeth while encouraging a return to normal function as soon as possible To encourage gingival healing, Parents should clean the affected area with a soft brush or cotton swab combined with an alcohol-free 0.1%–0.2% mouth rinse chlorhexidine gluconate applied topically twice a day for 1 wk <p>Follow up</p> <ul style="list-style-type: none"> Clinical examination after: <ul style="list-style-type: none"> 1 wk 6–8 wk Radiographic follow up only indicated where clinical findings are suggestive of pathosis (eg, an unfavorable outcome) Parents should be informed to watch for any unfavorable outcomes and the need to return to the clinic as soon as possible. Where unfavorable outcomes are identified, treatment is often required The follow-up treatment, which frequently requires the expertise of a child-oriented team, is outside the scope of these guidelines | <p>Favorable outcome</p> <ul style="list-style-type: none"> Asymptomatic Pulp healing with: <ul style="list-style-type: none"> Normal color of the crown or transient red/gray or yellow discoloration and pulp canal obliteration No signs of pulp necrosis and infection Continued root development in immature teeth No disturbance to the development and/or eruption of the permanent successor <p>Unfavorable outcome</p> <ul style="list-style-type: none"> Symptomatic Signs of pulp necrosis and infection—such as: <ul style="list-style-type: none"> Sinus tract, gingival swelling, abscess, or increased mobility Persistent dark gray discoloration plus one or more other signs of root canal infection Radiographic signs of pulp necrosis and infection No further root development of immature teeth Negative impact on the development and/or eruption of the permanent successor |

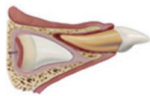
TABLE 8 Treatment guidelines for primary teeth: Subluxation

| Favorable and unfavorable outcomes include some, but not necessarily all, of the following | |
|---|---|
| Favorable outcome | Unfavorable outcome |
| <p>Subluxation</p>  <p>Clinical findings: The tooth is tender to touch and it has increased mobility, but it has not been displaced</p> <ul style="list-style-type: none"> Bleeding from gingival crevice may be noted <p>Radiographic recommendations and findings</p> <ul style="list-style-type: none"> A periapical (size 0 sensor/film, paralleling technique) or occlusal radiograph (size 2 sensor/film) should be taken at the time of initial presentation for diagnostic purposes and to establish a baseline Normal to slightly widened periodontal ligament space will be visible <p>Treatment</p> <ul style="list-style-type: none"> No treatment is needed. Observation Parent/patient education: <ul style="list-style-type: none"> Exercise care when eating not to further traumatize the injured teeth while encouraging a return to normal function as soon as possible To encourage gingival healing, Parents should clean the affected area with a soft brush or cotton swab combined with an alcohol-free 0.1%–0.2% chlorhexidine gluconate mouth rinse applied topically twice a day for 1 wk <p>Follow up</p> <ul style="list-style-type: none"> Clinical examination after: <ul style="list-style-type: none"> 1 wk 6–8 wk Where there are concerns that an unfavorable outcome is likely, then continue clinical follow up each year until eruption of the permanent teeth Radiographic follow up only indicated where clinical findings are suggestive of pathosis (eg, an unfavorable outcome) Parents should be informed to watch for any unfavorable outcomes and the need to return to the clinic as soon as possible. Where unfavorable outcomes are identified, treatment is often required The follow-up treatment, which frequently requires the expertise of a child-oriented team, is outside the scope of these guidelines | <p>Favorable outcome</p> <ul style="list-style-type: none"> Asymptomatic Pulp healing with: <ul style="list-style-type: none"> Normal color of the crown or transient red/gray or yellow discoloration and pulp canal obliteration No signs of pulp necrosis and infection Continued root development in immature teeth No disturbance to the development and/or eruption of the permanent successor <p>Unfavorable outcome</p> <ul style="list-style-type: none"> Symptomatic Signs of pulp necrosis and infection—such as: <ul style="list-style-type: none"> Sinus tract, gingival swelling, abscess, or increased mobility Persistent dark gray discoloration plus one or more signs of root canal infection Radiographic signs of pulp necrosis and infection No further root development of immature teeth Negative impact on the development and/or eruption of the permanent successor |

Reprinted with permission of John Wiley and Sons.


© 2020 The Authors. *Dental Traumatology* 2020;36(4):343–359. Available at: "https://onlinelibrary.wiley.com/doi/abs/10.1111/edt.12576". *Dental Traumatology* is published for the International Association of Dental Traumatology (IADT) by John Wiley and Sons Ltd.

TABLE 9 Treatment guidelines for primary teeth: Extrusive luxation

| Radiographic recommendations and findings | | Treatment | Follow up | Favorable outcome | Unfavorable outcome |
|---|--|--|---|---|--|
| <p>Extrusive luxation</p>  <p>Clinical findings: Partial displacement of the tooth out of its socket</p> <ul style="list-style-type: none"> The tooth appears elongated and can be excessively mobile. Occlusal interference may be present | <ul style="list-style-type: none"> A periapical (size 0 sensor/film, paralleling technique) or occlusal radiograph (size 2 sensor/film) should be taken at the time of initial presentation for diagnostic purposes and to establish a baseline Slight increase to substantially widened periodontal ligament space apically | <ul style="list-style-type: none"> Treatment decisions are based on the degree of displacement, mobility, interference with the occlusion, root formation, and the ability of the child to tolerate the emergency situation If the tooth is not interfering with the occlusion—let the tooth spontaneously reposition itself If the tooth is excessively mobile or extruded > 3 mm, then extract under local anesthesia Treatment should be performed by a child-oriented team with experience and expertise in the management of pediatric dental injuries. Extractions have the potential to cause long-term dental anxiety Parent/patient education: <ul style="list-style-type: none"> Exercise care when eating not to further traumatize the injured tooth while encouraging a return to normal function as soon as possible. To encourage gingival healing and prevent plaque accumulation, parents should clean the affected area with a soft brush or cotton swab combined with an alcohol-free 0.1%-0.2% chlorhexidine gluconate mouth rinse applied topically twice a day for 1 wk | <ul style="list-style-type: none"> Clinical examination after: <ul style="list-style-type: none"> - 1 wk - 6-8 wk - 1 y Where there are concerns that an unfavorable outcome is likely, then continue clinical follow up each year until eruption of the permanent teeth Radiographic follow up only indicated where clinical findings are suggestive of pathosis (eg, an unfavorable outcome) Parents should be informed to watch for any unfavorable outcomes and the need to return to the clinic as soon as possible. Where unfavorable outcomes are identified, treatment is often required The follow-up treatment, which frequently requires the expertise of a child-oriented team, is outside the scope of these guidelines | <ul style="list-style-type: none"> Asymptomatic Pulp healing with: <ul style="list-style-type: none"> - Normal color of the crown or transient red/gray or yellow discoloration and pulp canal obliteration - No signs of pulp necrosis and infection Continued root development in immature teeth Realignment of the extruded tooth No interference with the occlusion No disturbance to the development and/or eruption of the permanent successor | <ul style="list-style-type: none"> Symptomatic Signs of pulp necrosis and infection—such as: <ul style="list-style-type: none"> - Sinus tract, gingival swelling, abscess, or increased mobility - Persistent dark gray discoloration plus one or more signs of root canal infection Radiographic signs of pulp necrosis and infection No further root development of immature teeth No improvement in the position of the extruded tooth Negative impact on the development and/or eruption of the permanent successor |

Reprinted with permission of John Wiley and Sons.
 © 2020 The Authors. *Dental Traumatology* 2020;36(4):343-359. Available at: "https://onlinelibrary.wiley.com/doi/abs/10.1111/edt.12576".
Dental Traumatology is published for the International Association of Dental Traumatology (IADT) by John Wiley and Sons Ltd.

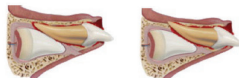
TABLE 10 Treatment guidelines for primary teeth: Lateral luxation

| Lateral luxation | Radiographic recommendations and findings | Treatment | Follow up | Favorable outcome | Unfavorable outcome |
|---|--|--|--|---|--|
|  | <ul style="list-style-type: none"> A periapical (size 0 sensor/film, paralleling technique) or occlusal radiograph (size 2 sensor/film) should be taken at the time of initial presentation for diagnostic purposes and to establish a baseline Increased periodontal ligament space apically (most clearly seen on an occlusal radiograph, especially if tooth is displaced labially) | <ul style="list-style-type: none"> If there is minimal or no occlusal interference, the tooth should be allowed to spontaneously reposition itself Spontaneous repositioning usually occurs within 6 mo In situations of severe displacement, two options are available, both of which require local anesthesia: <ul style="list-style-type: none"> Option A: <ul style="list-style-type: none"> Extraction when there is a risk of ingestion or aspiration of the tooth Option B: <ul style="list-style-type: none"> Gently reposition the tooth If unstable in its new position, splint for 4 wk using a flexible splint attached to the adjacent uninjured teeth Treatment should be performed by a child-oriented team with experience and expertise in the management of pediatric dental injuries. Extractions have the potential to cause long-term dental anxiety Parent/patient education: <ul style="list-style-type: none"> Exercise care when eating not to further traumatize the injured teeth while encouraging a return to normal function as soon as possible To encourage gingival healing and prevent plaque accumulation, parents should clean the affected area with a soft brush or cotton swab combined with an alcohol-free chlorhexidine gluconate 0.1%–0.2% mouth rinse applied topically twice a day for 1 wk | <ul style="list-style-type: none"> Clinical examination after: <ul style="list-style-type: none"> 1 wk 6–8 wk 6 mo 1 y If repositioned and splinted, review after: <ul style="list-style-type: none"> 1 wk 4 wk for splint removal 8 wk 6 mo 1 y Where there are concerns that an unfavorable outcome is likely, then continue clinical follow up each year until eruption of the permanent teeth Radiographic follow up only indicated where clinical findings are suggestive of pathosis (eg, an unfavorable outcome) Parents should be informed to watch for any unfavorable outcomes and the need to return to the clinic as soon as possible. Where unfavorable outcomes are identified, treatment is often required The follow-up treatment, which frequently requires the expertise of a child-oriented team, is outside the scope of these guidelines | <ul style="list-style-type: none"> Asymptomatic Pulp healing with: <ul style="list-style-type: none"> Normal color of the crown or transient red/gray or yellow discoloration and pulp canal obliteration No signs of pulp necrosis and infection <ul style="list-style-type: none"> Continued root development in immature teeth Periodontal healing Realignment of the laterally luxated tooth Normal occlusion No disturbance to the development and/or eruption of the permanent successor | <ul style="list-style-type: none"> Symptomatic Signs of pulp necrosis and infection—such as: <ul style="list-style-type: none"> Sinus tract, gingival swelling, abscess, or increased mobility Persistent dark gray discoloration plus one or more signs of root canal infection Radiographic signs of pulp necrosis and infection Ankylosis No further root development of immature teeth No improvement in position of the laterally luxated tooth Negative impact on the development and/or eruption of the permanent successor |

Reprinted with permission of John Wiley and Sons.

© 2020 The Authors. *Dental Traumatology* 2020;36(4):343–359. Available at: "https://onlinelibrary.wiley.com/doi/abs/10.1111/edt.12576". *Dental Traumatology* is published for the International Association of Dental Traumatology (IADT) by John Wiley and Sons Ltd.


TABLE 11 Treatment guidelines for primary teeth: Intrusive luxation

| Intrusive luxation | | Radiographic recommendations and findings | Treatment | Follow up | Favorable outcome | Unfavorable outcome |
|--|--|---|---|--|--|---------------------|
|  <p>Clinical findings: The tooth is usually displaced through the labial bone plate, or it can impinge on the permanent tooth bud</p> <ul style="list-style-type: none"> The tooth has almost or completely disappeared into the socket and can be palpated labially | <ul style="list-style-type: none"> A periapical (size 0 sensor/film, paralleling technique) or occlusal radiograph (size 2 sensor/film) should be taken at the time of initial presentation for diagnostic purposes and to establish a baseline When the apex is displaced toward or through the labial bone plate, the apical tip can be seen and the image of the tooth will appear shorter (foreshortened) than the contralateral tooth When the apex is displaced toward the permanent tooth germ, the apical tip cannot be visualized and the image of the tooth will appear elongated | <ul style="list-style-type: none"> The tooth should be allowed to spontaneously reposition itself, irrespective of the direction of displacement Spontaneous improvement in the position of the intruded tooth usually occurs within 6 mo In some cases, it can take up to 1 y A rapid referral (within a couple of days) to a child-oriented team that has experience and expertise in the management of pediatric dental injuries should be arranged Parent/patient education: <ul style="list-style-type: none"> Exercise care with eating not to further traumatize the injured tooth while encouraging a return to normal function as soon as possible To encourage gingival healing and prevent plaque accumulation, parents should clean the affected area with a soft brush or cotton swab combined with an alcohol-free 0.1%-0.2% chlorhexidine gluconate mouth rinse applied topically twice a day for 1 wk | <ul style="list-style-type: none"> Clinical examination after: <ul style="list-style-type: none"> 1 wk 6-8 wk 6 mo 1 y Further follow up at 6 y of age is indicated for severe intrusion to monitor eruption of the permanent tooth Radiographic follow up only indicated where clinical findings are suggestive of pathosis (eg, an unfavorable outcome) Parents should be informed to watch for any unfavorable outcomes and the need to return to the clinic as soon as possible. Where unfavorable outcomes are identified, treatment is often required The follow-up treatment, which frequently requires the expertise of a child-oriented team, is outside the scope of these guidelines | <ul style="list-style-type: none"> Asymptomatic Pulp healing with: <ul style="list-style-type: none"> Normal color of the crown or transient red/gray or yellow discoloration and pulp canal obliteration No signs of pulp necrosis and infection Continued root development in immature teeth Periodontal healing Re-eruption/realignment of the intruded tooth No disturbance to the development and/or eruption of the permanent successor | <ul style="list-style-type: none"> Symptomatic Signs of pulp necrosis and infection—such as: <ul style="list-style-type: none"> Sinus tract, gingival swelling, abscess, or increased mobility Persistent dark gray discoloration with one or more signs of infection Radiographic signs of pulp necrosis and infection No further root development of immature teeth Ankylosis Negative impact on the development and/or eruption of the permanent successor | |

Reprinted with permission of John Wiley and Sons.

© 2020 The Authors. *Dental Traumatology* 2020;36(4):343-359. Available at: "https://onlinelibrary.wiley.com/doi/abs/10.1111/edt.12576".
Dental Traumatology is published for the International Association of Dental Traumatology (IADT) by John Wiley and Sons Ltd.

TABLE 12 Treatment guidelines for primary teeth: Avulsion

| Avulsion | Radiographic recommendations and findings | Treatment | Follow up | Favorable outcome | Unfavorable outcome |
|--|--|---|---|---|---|
|  <p data-bbox="327 640 414 693">Clinical findings: The tooth is completely out of the socket</p> <ul data-bbox="327 703 414 966" style="list-style-type: none"> The location of the missing tooth should be explored during the trauma history and examination, especially when the accident was not witnessed by an adult or there was a loss of consciousness. While avulsed teeth are most often lost out of the mouth, there is a risk that they can be embedded in soft tissues of the lip, cheek, or tongue, pushed into the nose, ingested or aspirated. If the avulsed tooth is not found, the child should be referred for medical evaluation to an emergency room for further examination, especially where there are respiratory symptoms | <ul style="list-style-type: none"> A periapical (size 0 sensor/film, paralleling technique) or occlusal radiograph (size 2 sensor/film) is essential where the primary tooth is not brought into the clinic to ensure that the missing tooth has not been intruded The radiograph will also provide a baseline for assessment of the developing permanent tooth and to determine whether it has been displaced | <ul style="list-style-type: none"> Avulsed primary teeth should not be replanted Parent/patient education: <ul style="list-style-type: none"> Exercise care when eating not to further traumatize the injured soft tissues To encourage gingival healing and prevent plaque accumulation, parents should clean the affected area with a soft brush or cotton swab combined with an alcohol-free 0.1%-0.2% chlorhexidine gluconate mouth rinse applied topically twice a day for 1 wk | <ul style="list-style-type: none"> Clinical examination after: <ul style="list-style-type: none"> 6-8 wk Further follow up at 6 y of age is indicated to monitor eruption of the permanent tooth Radiographic follow up only indicated where clinical findings are suggestive of pathosis (eg, an unfavorable outcome) Parents should be informed to watch for any unfavorable outcomes and the need to return to the clinic as soon as possible. Where unfavorable outcomes are identified, treatment is often required The follow-up treatment, which frequently requires the expertise of a child-oriented team, is outside the scope of these guidelines | <ul style="list-style-type: none"> No signs of disturbance to development and/or eruption of the permanent successor | <ul style="list-style-type: none"> Negative impact on the development and/or eruption of the permanent successor |

Reprinted with permission of John Wiley and Sons.

© 2020 The Authors. *Dental Traumatology* 2020;36(4):343-359. Available at: "<https://onlinelibrary.wiley.com/doi/abs/10.1111/edt.12576>".
Dental Traumatology is published for the International Association of Dental Traumatology (IADT) by John Wiley and Sons Ltd.

A summary of the management of TDIs in the primary dentition includes the following:

- A child's maturity and ability to cope with the emergency situation, the time for shedding of the injured tooth, and the occlusion are all important factors that influence treatment.
- It is critical that parents are given appropriate advice on how best to manage the acute symptoms to avoid further distress.^{48,49} Luxation injuries, such as intrusion and lateral luxation, and root fractures may cause severe pain. The use of analgesics such as ibuprofen and/or acetaminophen (paracetamol) is recommended when pain is anticipated.
- Minimizing dental anxiety is essential. Provision of dental treatment depends on the child's maturity and ability to cope. Various behavioral approaches are available⁵⁰⁻⁵¹ and have been shown to be effective for managing acute procedures in an emergency situation.^{52,53} TDIs and their treatment have the potential to lead to both post-traumatic stress disorder and dental anxiety. The development of these conditions in young children is a complex issue^{54,55} with little research specifically examining either condition following TDIs in the primary dentition. However, evidence from the wider dental literature suggests that the multi-factorial nature of dental anxiety, its fluctuating nature, and the role of dental extractions are exacerbating factors.⁵⁶⁻⁵⁸ Where possible, avoidance of dental extractions, especially at the acute or initial visit, is a reasonable strategy.
- Where appropriate and the child's cooperation allows, options that maintain the child's primary dentition should be the priority.⁵⁹ Discussions with parents about the different treatment options should include the potential for further treatment visits and consideration for how best to minimize the impact of the injury on the developing permanent dentition.⁶⁰
- For crown and crown-root fractures involving the pulp, root fractures, and luxation injuries, rapid referral within several days to a child-oriented team that has experience and expertise in the management of dental injuries in children is essential.
- Splinting is used for alveolar bone fractures^{60,61} and occasionally may be needed in cases of root fractures⁶² and lateral luxations.⁶²

1.10 | Avulsed primary teeth

An avulsed primary tooth should not be replanted. Reasons include a significant treatment burden (including replantation, splint placement and removal, root canal treatment) for a young child as well as the potential of causing further damage to the permanent tooth or to its eruption.^{40,41,63,64} However, the most important reason is to avoid a medical emergency resulting from aspiration of the tooth. Careful follow up is required to monitor the development and eruption of the permanent tooth. Refer to the accompanying table () for specific guidance.

1.11 | Antibiotics and Tetanus

There is no evidence for recommending the use of systemic antibiotics in the management of luxation injuries in the primary dentition. However, antibiotic use does remain at the discretion of the clinician when TDIs are accompanied by soft tissue and other associated injuries or significant surgical intervention is required. Finally, the child's medical status may warrant antibiotic coverage. The child's pediatrician should be contacted where questions arise in these situations.

A tetanus booster may be required if environmental contamination of the injury has occurred. If in doubt, refer to a medical practitioner within 48 hours.

1.12 | Parental instructions for homecare

Successful healing following an injury to the teeth and oral tissues depends on good oral hygiene. To optimize healing, parents or caregivers should

be advised regarding care of the injured tooth/teeth and the prevention of further injury by supervising potentially hazardous activities. Clean the affected area with a soft brush or cotton swab and use alcohol-free chlorhexidine gluconate 0.12% mouth rinse applied topically twice a day for one week to prevent accumulation of plaque and debris and to reduce the bacterial load. Care should be taken when eating not to further traumatize the injured teeth while encouraging a return to normal function as soon as possible.

Parents or caregivers should be advised about possible complications that may occur, such as swelling, increased mobility, or a sinus tract. Children may not complain about pain, but infection may be present. Parents or caregivers should watch for signs of infection such as swelling of the gums. If present, they should take the child to a dentist for treatment. Examples of unfavorable outcomes are found in the table for each injury (Tables 1-12).

1.13 | Training, skills, and experience for teams managing the follow-up care

During the follow-up phase of treatment, dental teams caring for children with complex injuries to the primary dentition should have specialist training, experience, and skills. These attributes enable the members of the team to respond appropriately to the medical, physical, emotional, and developmental needs of children and their families. In addition, skills within the team should also encompass health promotion and access to specialist diagnostic and treatment services including sedation, general anesthesia, and overall pain management for the prevention or minimization of suffering.¹⁹

1.14 | Prognosis

Factors relating to the injury and subsequent treatment may influence pulp and periodontal outcomes, and they should be carefully recorded. These prognostic factors need to be carefully collected at both the initial consultation and follow-up visits. This is most likely achieved using the structured history form described previously. The dental literature and appropriate websites (eg, www.dentaltraumaguide.org) provide clinicians with useful information on the probable pulp and periodontal prognosis. These sources of information can be invaluable when having conversations with the parents or caregivers and the child.

1.15 | Core outcome set

The International Association for Dental Traumatology (IADT) recently developed a core outcome set (COS) for traumatic dental injuries (TDIs) in children and adults.⁶⁵ This is one of the first COS developed in dentistry and is underpinned by a systematic review of the outcomes used in the trauma literature and follows a robust consensus methodology.⁶⁶ Some outcomes were identified as recurring throughout the different injury types. These outcomes were then identified as "generic" (ie, relevant to all TDIs). Injury-specific outcomes were also determined as those outcomes related only to one or more individual TDIs. Additionally, the study established what, how, when, and by whom these outcomes should be measured. Table 1 in the General Introduction section⁶⁷ of the Guidelines shows the generic and injury-specific outcomes to be recorded at the follow-up review appointments recommended for the different traumatic injuries. Further information for each outcome is described in the original article.⁶⁵

CONFLICT OF INTEREST

The authors declare there is no competing interest for the above manuscript. Images courtesy of the Dental Trauma Guide.

ETHICAL STATEMENT

No ethics approval was required for this paper

Reprinted with permission of John Wiley and Sons.

© 2020 The Authors. *Dental Traumatology* 2020;36(4):343-359. Available at: "<https://onlinelibrary.wiley.com/doi/abs/10.1111/edt.12576>".
Dental Traumatology is published for the International Association of Dental Traumatology (IADT) by John Wiley and Sons Ltd.

ORCID

Peter F. Day  <https://orcid.org/0000-0001-9711-9638>
 Marie Therese Flores  <https://orcid.org/0000-0003-2412-190X>
 Anne C. O'Connell  <https://orcid.org/0000-0002-1495-3983>
 Paul V. Abbott  <https://orcid.org/0000-0001-5727-4211>
 Georgios Tsilingaridis  <https://orcid.org/0000-0001-5361-5840>
 Ashraf F. Fouad  <https://orcid.org/0000-0001-6368-1665>
 Nestor Cohenca  <https://orcid.org/0000-0002-0603-5437>
 Eva Lauridsen  <https://orcid.org/0000-0003-0859-7262>
 Cecilia Bourguignon  <https://orcid.org/0000-0003-2753-649X>
 Bill Kahler  <https://orcid.org/0000-0002-4181-3871>
 Liran Levin  <https://orcid.org/0000-0002-8123-7936>

REFERENCES

- Sleet DA. The global challenge of child injury prevention. *Int J Environ Res Public Health*. 2018;15(9):1921.
- Petersson EE, Andersson L, Sorensen S. Traumatic oral vs non-oral injuries. *Swed Dent J*. 1997;21:55–68.
- Petti S, Glendor U, Andersson L. World traumatic dental injury prevalence and incidence, a meta-analysis-One billion living people have had traumatic dental injuries. *Dent Traumatol*. 2018;34:71–86.
- Glendor U. Epidemiology of traumatic dental injuries - a 12 year review of the literature. *Dent Traumatol*. 2008;24:603–11.
- Andersson L, Petti S, Day P, Kenny K, Glendor U, Andreasen JO. Classification, epidemiology and etiology. In: Andreasen JO, Andreasen FM, Andersson L, editors. *Textbook and color atlas of traumatic injuries to the teeth*, 5th edn. Copenhagen: Wiley Blackwell; 2019. p. 252–94.
- Glendor U, Halling A, Andersson L, Eilert-Petersson E. Incidence of traumatic tooth injuries in children and adolescents in the county of Vastmanland, Sweden. *Swed Dent J*. 1996;20:15–28.
- Andreasen JO, Ravn JJ. Epidemiology of traumatic dental injuries to primary and permanent teeth in a Danish population sample. *Int J Oral Surg*. 1972;1:235–9.
- Borum MK, Andreasen JO. Sequelae of trauma to primary maxillary incisors. I. Complications in the primary dentition. *Endod Dent Traumatol*. 1998;14:31–44.
- Kupietzky A, Holan G. Treatment of crown fractures with pulp exposure in primary incisors. *Pediatr Dent*. 2003;25:241–7.
- Holan G, Ram D. Sequelae and prognosis of intruded primary incisors: a retrospective study. *Pediatr Dent*. 1999;21:242–7.
- Assuncao LR, Ferelle A, Iwakura ML, Nascimento LS, Cunha RF. Luxation injuries in primary teeth: a retrospective study in children assisted at an emergency service. *Braz Oral Res*. 2011;25:150–6.
- Qassem A, Martins NM, da Costa VP, Torriani DD, Pappen FG. Longterm clinical and radiographic follow up of subluxated and intruded maxillary primary anterior teeth. *Dent Traumatol*. 2015;31:57–61.
- Tannure PN, Fidalgo TK, Barcelos R, Primo LG, Maia LC. Analysis of root canal treated primary incisor after trauma: two year outcomes. *J Clin Pediatr Dent*. 2012;36:257–62.
- Cardoso M, Rocha MJ. Federal University of Santa Catarina follow-up management routine for traumatized primary teeth - Part 1. *Dent Traumatol*. 2004;20:307–13.
- Soprowski NJ, Allred EN, Needleman HL. Luxation injuries of primary anterior teeth—prognosis and related correlates. *Pediatr Dent*. 1994;16:96–101.
- Andreasen JOAF, Bakland LK, Flores MT. *Traumatic dental injuries, a manual*, 3rd edn. Chichester, UK: Wiley-Blackwell; 2011.
- Andreasen FM, Andreasen JO, Tsukiboshi M, Cohenca N. Examination and diagnosis of dental injuries. In: Andreasen JO, Andreasen FM, Andersson L, editors. *Textbook and color atlas of traumatic injuries to the teeth*, 5th edn. Copenhagen, Denmark: Wiley Blackwell; 2019. p. 295–326.
- Flores MT, Holan G, Andreasen JO, Lauridsen E. Injuries to the primary dentition. In: Andreasen JO, Andreasen FM, Andersson L, editors. *Textbook and color atlas of traumatic injuries to the teeth*, 5th edn. Copenhagen, Denmark: Wiley Blackwell; 2019. p. 556–88.
- World Medical Association. Declaration of Ottawa on Child Health. 2009; <https://www.wma.net/policies-post/wma-declaration-of-ottawa-on-child-health/>. Accessed June 4, 2020.
- Day PF, Duggal MS. A multicentre investigation into the role of structured histories for patients with tooth avulsion at their initial visit to a dental hospital. *Dent Traumatol*. 2003;19:243–7.
- Day PF, Duggal MS. The role of 'reminders' in dental traumatology: 1. Current practices in the UK and Ireland. *Dent Traumatol*. 2006;22:247–51.
- Andreasen JO. Appendix 1 and 2. In: Andreasen JO, Andreasen FM, Andersson L, eds. *Textbook and color atlas of traumatic injuries to the teeth*, 5th edn. Copenhagen, Denmark: Wiley Blackwell, 2019; p. 1020–3.
- Andersson L, Andreasen JO. Soft tissue injuries. In: Andreasen JO, Andreasen FM, Andersson L, editors. *Textbook and color atlas of traumatic injuries to the teeth*, 5th edn. Copenhagen, Denmark: Wiley Blackwell; 2019. p. 626–44.
- Soares TR, Barbosa AC, Oliveira SN, Oliveira EM, Risso Pde A, Maia LC. Prevalence of soft tissue injuries in pediatric patients and its relationship with the quest for treatment. *Dent Traumatol*. 2016;32:48–51.
- Lauridsen E, Blanche P, Amaloo C, Andreasen JO. The risk of healing complications in primary teeth with concussion or subluxation injury - a retrospective cohort study. *Dent Traumatol*. 2017;33:337–44.
- Lauridsen E, Blanche P, Yousaf N, Andreasen JO. The risk of healing complications in primary teeth with intrusive luxation: A retrospective cohort study. *Dent Traumatol*. 2017;33:329–36.
- Lauridsen E, Blanche P, Yousaf N, Andreasen JO. The risk of healing complications in primary teeth with extrusive or lateral luxation - A retrospective cohort study. *Dent Traumatol*. 2017;33:307–16.
- Auslander WP. Discoloration, a traumatic sequela. *NY State Dent J*. 1967;33:534–8.
- Jacobsen I, Sangnes G. Traumatized primary anterior teeth. Prognosis related to calcific reactions in the pulp cavity. *Acta Odontol Scand*. 1978;36:199–204.
- Fried I, Erickson P, Schwartz S, Keenan K. Subluxation injuries of maxillary primary anterior teeth: epidemiology and prognosis of 207 traumatized teeth. *Pediatr Dent*. 1996;18:145–51.
- Holan G, Fuks AB. The diagnostic value of coronal dark-gray discoloration in primary teeth following traumatic injuries. *Pediatr Dent*. 1996;18:224–7.
- Holan G. Development of clinical and radiographic signs associated with dark discolored primary incisors following traumatic injuries: a prospective controlled study. *Dent Traumatol*. 2004;20:276–87.
- Holan G. Long-term effect of different treatment modalities for traumatized primary incisors presenting dark coronal discoloration with no other signs of injury. *Dent Traumatol*. 2006;22:14–7.
- Law CS, Douglass JM, Farman AG, White SC, Zeller GG, Lurie AG, et al. The image gently in dentistry campaign: partnering with parents to promote the responsible use of x-rays in pediatric dentistry. *Pediatr Dent*. 2014;36:458–9.
- White SC, Scarfe WC, Schulze RK, Lurie AG, Douglass JM, Farman AG. The Image Gently in Dentistry campaign: promotion of responsible use of maxillofacial radiology in dentistry for children. *Oral Surg Oral Med Oral Pathol Oral Radiol*. 2014;118:257–61.
- Sodhi KS, Krishna S, Saxena AK, Sinha A, Khandelwal N, Lee EY. Clinical application of 'Justification' and 'Optimization' principle of ALARA in pediatric CT imaging: "How many children can be protected from unnecessary radiation?". *Eur J Radiol*. 2015;84:1752–7.

Reprinted with permission of John Wiley and Sons.

© 2020 The Authors. *Dental Traumatology* 2020;36(4):343-359. Available at: "<https://onlinelibrary.wiley.com/doi/abs/10.1111/edt.12576>".
Dental Traumatology is published for the International Association of Dental Traumatology (IADT) by John Wiley and Sons Ltd.

37. Andreassen JO, Flores MT, Lauridsen E. Injuries to developing teeth. In: Andreassen JO, Andreassen FM, Andersson L, editors. Textbook and color atlas of traumatic injuries to the teeth, 5th edn. Copenhagen, Denmark: Wiley Blackwell; 2019. p. 589–625.
38. Andreassen JO, Ravn JJ. The effect of traumatic injuries to primary teeth on their permanent successors. II. A clinical and radiographic follow-up study of 213 teeth. *Scand J Dent Res*. 1971;79:284–94.
39. Da Silva Assuncao LR, Ferelle A, Iwakura ML, Cunha RF. Effects on permanent teeth after luxation injuries to the primary predecessors: a study in children assisted at an emergency service. *Dent Traumatol*. 2009;25:165–70.
40. Flores MT, Onetto JE. How does orofacial trauma in children affect the developing dentition? Long-term treatment and associated complications. *Dent Traumatol*. 2019;35:312–23.
41. Lenzi MM, da Silva Fidalgo TK, Luiz RR, Maia LC. Trauma in primary teeth and its effect on the development of permanent successors: a controlled study. *Acta Odontol Scand*. 2018;22:1–6.
42. Lenzi MM, Alexandria AK, Ferreira DM, Maia LC. Does trauma in the primary dentition cause sequelae in permanent successors? A systematic review. *Dent Traumatol*. 2015;31:79–88.
43. Altun C, Cehreli ZC, Güven G, Acikel C. Traumatic intrusion of primary teeth and its effects on the permanent successors: a clinical follow-up study. *Oral Surg Oral Med Oral Pathol Oral Radiol Endod*. 2009;107:493–8.
44. Spinass E, Melis A, Savasta A. Therapeutic approach to intrusive luxation injuries in primary dentition. A clinical follow-up study. *Eur J Paed Dent*. 2006;7:179–86.
45. Colak I, Markovic D, Petrovic B, Peric T, Milenkovic A. A retrospective study of intrusive injuries in primary dentition. *Dent Traumatol*. 2009;25:605–10.
46. Flores MT. Traumatic injuries in the primary dentition. *Dent Traumatol*. 2002;18:287–98.
47. Cunha RF, Pugliesi DM, Percinoto C. Treatment of traumatized primary teeth: a conservative approach. *Dent Traumatol*. 2007;23:360–3.
48. Martens LC, Rajasekharan S, Jacquet W, Vandenbulcke JD, Van Acker JWG, Cauwels RGE. Paediatric dental emergencies: a retrospective study and a proposal for definition and guidelines including pain management. *Eur Arch Paediat Dent*. 2018;19:245–53.
49. Whiston C, Ali S, Wright B, Wonnacott D, Stang AS, Thompson GC, et al. Is caregiver refusal of analgesics a barrier to pediatric emergency pain management? A cross-sectional study in two Canadian centres. *CJEM*. 2018;20:892–902.
50. Roberts JF, Curzon ME, Koch G, Martens LC. Review: behaviour management techniques in paediatric dentistry. *Eur Arch Paediat Dent*. 2010;11:166–74.
51. American Academy of Pediatric Dentistry. Behaviour guidance for the pediatric dental patient. *Pediatr Dent*. 2015;40:254–67.
52. Ali S, McGrath T, Drendel AL. An evidence-based approach to minimizing acute procedural pain in the emergency department and beyond. *Pediatr Emerg Care*. 2016;32:36–42.
53. Pancekauskaite G, Jankauskaite L. Paediatric pain medicine: pain differences, recognition and coping acute procedural pain in paediatric emergency room. *Medicina*. 2018;54(6):94.
54. De Young AC, Kenardy JA, Cobham VE. Trauma in early childhood: a neglected population. *Clin Child Fam Psychol Rev*. 2011;14:231–50.
55. Stoddard FJ Jr. Outcomes of traumatic exposure. *Child Adolesc Psychiatr Clin N Am*. 2014;23:243–56.
56. Tickle M, Jones C, Buchannan K, Milsom KM, Blinkhorn AS, Humphris GM. A prospective study of dental anxiety in a cohort of children followed from 5 to 9 years of age. *Int J Paediatr Dent*. 2009;19:225–32.
57. Milsom KM, Tickle M, Humphris GM, Blinkhorn AS. The relationship between anxiety and dental treatment experience in 5-year-old children. *Br Dent J*. 2003;194:503–6.
58. Soares FC, Lima RA, de Barros MVG, Dahlöf G, Colares V. Development of dental anxiety in schoolchildren: a 2-year prospective study. *Community Dent Oral Epidemiol*. 2017;45:281–8.
59. Holan G, Needleman HL. Premature loss of primary anterior teeth due to trauma—potential short- and long-term sequelae. *Dent Traumatol*. 2014;30:100–6.
60. Holan G, Topf J, Fuks AB. Effect of root canal infection and treatment of traumatized primary incisors on their permanent successors. *Dent Traumatol*. 1992;8:12–5.
61. Akin A, Uysal S, Cehreli ZC. Segmental alveolar process fracture involving primary incisors: treatment and 24-month follow up. *Dent Traumatol*. 2011;27:63–6.
62. Cho WC, Nam OH, Kim MS, Lee HS, Choi SC. A retrospective study of traumatic dental injuries in primary dentition: treatment outcomes of splinting. *Acta Odontol Scand*. 2018;76:253–6.
63. Tewari N, Mathur VP, Singh N, Singh S, Pandey RK. Long-term effects of traumatic dental injuries of primary dentition on permanent successors: a retrospective study of 596 teeth. *Dent Traumatol*. 2018;34:129–34.
64. de Amorim LF, da Costa LR, Estrela C. Retrospective study of traumatic dental injuries in primary teeth in a Brazilian specialized pediatric practice. *Dent Traumatol*. 2011;27:368–73.
65. Kenny KP, Day PF, Sharif MO, Parashos P, Lauridsen E, Feldens CA. What are the important outcomes in traumatic dental injuries? An international approach to the development of a core outcome set. *Dent Traumatol*. 2018;34:4–11.
66. Sharif MO, Tejani-Sharif A, Kenny K, Day PF. A systematic review of outcome measures used in clinical trials of treatment interventions following traumatic dental injuries. *Dent Traumatol*. 2015;31:422–8.
67. Levin L, Day PF, Hicks L, O'Connell AC, Fouad AF, Bourguignon C, et al. International Association of Dental Traumatology guidelines for the management of traumatic dental injuries: General Introduction. *Dent Traumatol*. 2020;36:309–13.

Reprinted with permission of John Wiley and Sons.

© 2020 The Authors. *Dental Traumatology* 2020;36(4):343–359. Available at: "<https://onlinelibrary.wiley.com/doi/abs/10.1111/edt.12576>".
Dental Traumatology is published for the International Association of Dental Traumatology (IADT) by John Wiley and Sons Ltd.